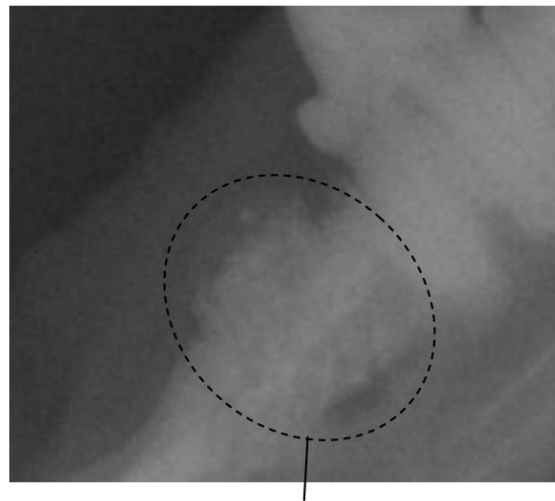
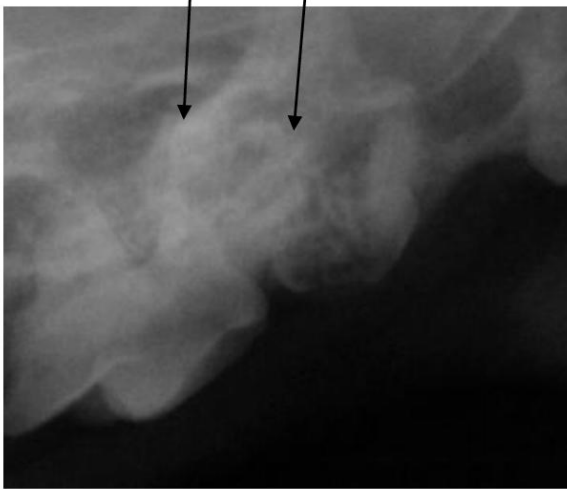

Resorptive Lesion

This is a lesion where the tooth breaks down from the cementum layer of the tooth. This is the layer of the tooth that holds the root to the bone. It will then progress and spread throughout the tooth, either dissolving the root or causing a weakness in the crown of the tooth (the part of the tooth you can see). These are found commonly in cats, and we are now starting to see more of these lesions in dogs. Unfortunately, the only way to cure these lesions is removal of the tooth

Roots of teeth that are being resorbed by the body



Tooth that has almost been completely resorbed

Suspected teeth with resorptive lesions

